

Cerebral Hemorrhage After Passive Anti-A β Immunotherapy

M. Pfeifer,¹ S. Boncristiano,¹ L. Bondolfi,¹ A. Stalder,¹ T. Deller,² M. Staufenbiel,³ P. M. Mathews,⁴ M. Jucker^{1*}

Immunotherapy for Alzheimer's disease (AD) has been the subject of intense investigation. Both active and passive immunization against β -amyloid peptide (A β) in mouse models reduce levels of A β , prevent and clear amyloid plaques, and improve cognitive behavior (1). We studied passive immunization of APP23 transgenic mice, a model that exhibits the age-related development of amyloid plaques and neurodegeneration as well as cerebral amyloid angiopathy (CAA) similar to that observed in the human AD brain (2, 3). Consistent with earlier reports, we found that passive A β immunization results in a significant reduction of mainly diffuse amyloid. However, it also induces an increase in cerebral microhemorrhages associated with amyloid-laden vessels, suggesting a possible link to the neuroinflammatory complications of A β immunization recently seen in a human trial (1).

Male 21-month-old APP23 mice ($n = 10$) were passively immunized weekly by intraperitoneal injections of 0.5 mg of β 1 mouse monoclonal immunoglobulin G₁ antibody that recognizes amino acids 3 to 6 of human A β (4). Age-matched APP23 control mice were injected with phosphate-buffered saline ($n = 11$). After 5 months of treatment, stereological analysis of amyloid load (4) revealed a significant amyloid reduction (23%; $P = 0.0008$) in neocortex of the immunized mice compared with controls (Fig. 1, A and B). This reduction was largely accounted for by a reduction (33%; $P = 0.001$) in diffuse amyloid. Enzyme-linked immunosorbent assay measurements of formic acid extracted brain samples (4) showed a significant reduction in A β 42 (44.8 ± 2.7 and 34.7 ± 3.1 μ g/g wet weight for control and immunized mice, respectively; $P = 0.03$), but no significant reduction in A β 40 (166.2 ± 11.3 compared with 152.7 ± 12.2 μ g/g).

CAA frequency and severity (4) were not affected by immunization. However, immunized mice exhibited a more than twofold increase in the frequency of CAA-associated cerebral hemorrhage as well as a significant increase in hemorrhage severity over controls (Fig. 1, C to

J). Most hemorrhages could clearly be attributed to amyloid-laden vessels, and bleedings only occurred in brain areas affected with CAA. Moreover, we found six acute hematomas in immunized mice compared with only one hematoma in control mice. Similar immunization of 6-month-old APP23 mice ($n = 12$), which exhibited modest parenchymal amyloid but lacked significant CAA, revealed no hemorrhages.

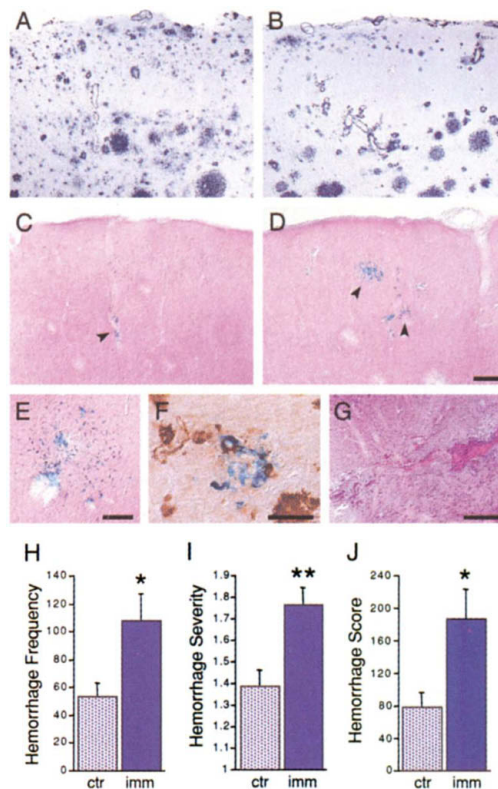


Fig. 1. Amyloid pathology in the neocortex of a control (A) and an age-matched immunized APP23 mouse (B). Hemisiderin staining reveals an increased number of microhemorrhages (arrowheads) in the immunized (D) compared with control mice (C). Hemorrhages in the immunized mice often reached considerable sizes (E). Double staining for hemisiderin (blue) and A β (brown) demonstrates that most bleedings were associated with amyloid-laden vessels (F). H&E staining reveals a fresh bleed in an immunized mouse (G). Quantification (4) of microhemorrhage frequency per unilateral neocortex (H) revealed a more than twofold increase in immunized (imm) compared with control (ctr) mice (* $P = 0.02$). Hemorrhage severity (I) and hemorrhage score (J) also showed significant increases (** $P = 0.003$ and * $P = 0.01$). Scale bars are 100 μ m (A to D), 100 μ m (E), 20 μ m (F), and 200 μ m (G).

Deposition of amyloid in cerebral blood vessels leads to a loss of smooth muscle cells and a weakening of the vessel wall in mice and humans (5, 6). Our findings suggest that passive A β immunization increases the risk of cerebral hemorrhage by further weakening of the amyloidotic vessel wall. A potential mechanism is that antibody binding to vascular amyloid triggers a local inflammatory reaction, which might be sufficient to destabilize the already weakened vessel wall (6). A link between AD-type vascular pathology and inflammation has been suggested (7). Alternatively, antibody binding to soluble A β in blood may lead to increased vascular permeability with a concomitant invasion of plasma proteins and diapedesis that in turn may increase the risk of hemorrhage (6, 8). We found no evidence for involvement of the extrinsic coagulation cascade, although we have previously reported that thrombolytic treatment enhances hemorrhagic diathesis in APP23 mice (4).

No adverse side effects have been reported in other mouse A β immunization paradigms; however, the mouse models used in those studies do not develop significant CAA (1). As over 10% of people beyond 65 years of age and 80% of AD cases exhibit CAA (9, 10), anti-A β immunotherapy protocols may be best developed in mouse models that show CAA in addition to brain parenchyma amyloid deposits. Although the anti-NH₂-terminal A β antibody used in this study resulted in an increase in CAA-associated microhemorrhages, further screening of antibodies that recognize other A β epitopes or conformations may identify antibodies that do not have this effect. Although difficult to diagnose pre-mortem (10), our results also suggest that the success of A β immunotherapy may be improved by screening AD patients for the presence and severity of CAA before such therapies are undertaken.

References and Notes

1. D. Schenk, *Nature Rev. Neurosci.* **3**, 824 (2002).
2. C. Sturchler-Pierrat *et al.*, *Proc. Natl. Acad. Sci. U.S.A.* **94**, 13287 (1997).
3. M. E. Calhoun *et al.*, *Proc. Natl. Acad. Sci. U.S.A.* **96**, 14088 (1999).
4. See supplementary material on Science Online.
5. D. T. Winkler *et al.*, *J. Neurosci.* **21**, 1619 (2001).
6. A. Maeda *et al.*, *Stroke* **24**, 1857 (1993).
7. D. Paris *et al.*, *Neurobiol. Aging* **21**, 183 (2000).
8. J. F. Poduslo *et al.*, *Neuroreport* **12**, 3197 (2001).
9. K. A. Jellinger, *J. Neural Transm.* **109**, 813 (2002).
10. S. M. Greenberg, *Neurology* **51**, 690 (1998).
11. Supported by the Swiss National Science Foundation, the Alzheimer Forschung Initiative, and the National Institute on Aging. We thank D. Tsakiris, M. Mihatsch, A. Probst, D. Winkler, M. Zurini, G. Burbach, M. Mercken, L. Walker, M. Herzog, J. Ghiso, and S. Schmidt for advice and help.

Supporting Online Material

www.sciencemag.org/cgi/content/full/298/5597/1379/DC1
Methods and Materials

¹Institute of Pathology, University of Basel, CH-4003 Basel, Switzerland. ²Institute of Clinical Neuroanatomy, University of Frankfurt, D-60590 Frankfurt, Germany. ³Novartis Pharma, CH-4002 Basel, Switzerland. ⁴Nathan Kline Institute for Psychiatric Research, New York University School of Medicine, Orangeburg, NY 10962, USA.

*To whom correspondence should be addressed.
E-mail: mjucker@uhbs.ch