

Making Memories: Brain Activity that Predicts How Well Visual Experience Will Be Remembered

James B. Brewer,* Zuo Zhao, John E. Desmond, Gary H. Glover, John D. E. Gabrieli

Experiences are remembered or forgotten, but the neural determinants for the mnemonic fate of experience are unknown. Event-related functional magnetic resonance imaging was used to identify specific brain activations that differentiated between visual experiences that were later remembered well, remembered less well, or forgotten. During scanning of medial temporal lobe and frontal lobe regions, subjects viewed complex, color photographs. Subjects later received a test of memory for the photographs. The magnitudes of focal activations in right prefrontal cortex and in bilateral parahippocampal cortex predicted which photographs were later remembered well, remembered less well, or forgotten.

Studies of patients with brain damage have identified regions critical for declarative memory, the conscious or explicit memory for new events and facts (1). One region essential for declarative memory is the medial temporal lobe. Bilateral damage to this brain region yields global amnesia, a pervasive memory deficit for all new events and facts. Regions of the frontal lobes also contribute to declarative memory (2). Memory deficits subsequent to unilateral medial temporal lobe or frontal damage are often material-specific, with left-sided lesions impairing verbal memory, and right-sided lesions impairing nonverbal memory (3).

Lesion studies cannot distinguish whether a given brain region normally participates in the encoding of ongoing experiences into memories, or the storage of the memories over time, or the later retrieval of those memories. Functional neuroimaging studies can distinguish between encoding and retrieval by measuring brain activation at each stage of memory. Evidence for the participation of the medial temporal lobe in the encoding of memories has come from studies that found greater activation for

novel versus highly familiar visual scenes (4–6). The most consistent locus of activation occurred bilaterally in parahippocampal cortex, a major component of the medial temporal lobe system. In addition, one of the studies reported a similar activation in right frontal cortex (4).

Greater activation for novel versus repeated scenes may reflect the encoding of declarative memory, but other interpretations are equally plausible. One possibility

is that it reflects a response to novelty unrelated to the encoding of memory. Other possibilities are that it reflects habituation, reduced attention, or strategic differences resulting from the use of blocked designs, in which activation was averaged over long, predictable sequences of either many novel or many familiar scenes. Yet another possibility is that greater activation for novel versus repeated scenes could reflect implicit memory processes. Reduced activation for repeated materials in frontal and occipital regions are commonly interpreted as reflecting implicit memory (repetition priming) and not declarative, explicit memory (7). Thus, there is no direct evidence that greater parahippocampal or right-frontal activation for novel versus familiar scenes signifies processes relevant to encoding visual declarative memories.

Persuasive evidence that a particular brain activation signifies processes important for encoding declarative memories comes from event-related study designs, in which separate activations are recorded for each stimulus. Based on the outcome of a later test for memory, activations can be measured separately for stimuli encoded successfully (later remembered) or unsuccessfully (later forgotten) (8). Advances in functional magnetic resonance imaging (fMRI) now permit the measurement of event-related responses to individual experiences (stimuli) (9). Here we report that event-related activity during study in parahippocampal and right frontal areas differs

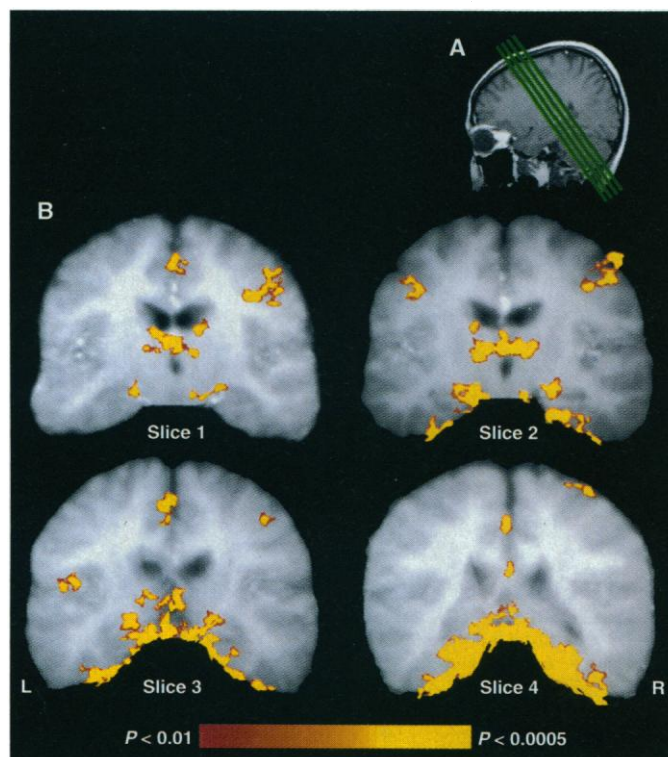


Fig. 1. (A) Locations of oblique MRI structural and functional images. The four slices, shown as green lines, are referred to as slices 1 to 4, from anterior to posterior, in subsequent figures. (B) Composite statistical activation maps superimposed on averaged structural MRI slices from six subjects. For all figures, the left side of the image corresponds to the left side of the brain. Voxels showing significantly greater activation for scenes than for fixation are shown as ranging from $P < 0.01$ (red) to $P < 0.0005$ (yellow).

J. B. Brewer, Neuroscience Program and School of Medicine, Stanford University, Stanford, CA 94305, USA. Z. Zhao and J. E. Desmond, Department of Psychology, Stanford University, Stanford, CA 94305, USA. G. H. Glover, Department of Radiology, Stanford University, Stanford, CA 94305, USA. J. D. E. Gabrieli, Department of Psychology and Neuroscience Program, Stanford University, Stanford, CA 94305, USA.

*To whom correspondence should be addressed at Neuroscience Program, Building 420 Jordan Hall, Stanford University, Stanford, CA 94305, USA. E-mail: brewer@psych.stanford.edu

REPORTS

for visual stimuli subsequently remembered or forgotten.

Six normal, right-handed subjects performed four fMRI scans (10) (Fig. 1A), each consisting of 24 color pictures of indoor and outdoor scenes that were selected to be similar in complexity and quality. During scanning, subjects judged whether each picture depicted an indoor or outdoor scene (11). Thirty minutes after scanning, subjects were given an unexpected memory test for the pictures viewed in the scanner. They saw the

96 previously seen pictures and 32 new pictures presented individually on a computer monitor and judged whether or not they had seen each picture during scanning. For pictures judged as previously seen, the subjects reported whether their judgment was based on a distinct recollection of having seen the picture ("remember") or a less certain feeling of familiarity ("know") (12). Thus, each studied picture had one of three memory outcomes—well remembered, familiar but not well remembered, or forgotten (pictures that

subjects had seen but denied having seen).

Of the studied pictures, subjects clearly remembered 25% (range, 5 to 47%), felt that 27% (range, 17 to 38%) were familiar, and forgot 48% (range, 25 to 66%). No particular group of pictures was better remembered than another across subjects. Memory for indoor and outdoor scenes did not differ ($P > 0.8$), and the particular pictures remembered varied greatly across subjects, in that the distribution of memory scores across items did not differ from the expected normal distribution ($P > 0.5$). Median response times for classification tended to be longer for pictures that would later be remembered (remembered = 725 ms, familiar = 671 ms, forgotten = 680 ms), but these differences were not reliable ($P > 0.15$).

Two activation maps based on voxel-wise statistics were constructed (13). The first map revealed event-related activity that was greater for pictures than for fixation. Multiple, bilateral regions responded significantly to the picture stimuli. These included dorsolateral prefrontal regions, thalamus, cingulate, caudate, fusiform, parahippocampus, and low-level visual areas such as the lateral geniculate nucleus and primary visual cortex (Fig. 1B).

A second map was based on a Kendall's rank order correlation of subsequent memory for the picture (that is, remembered, familiar, or forgotten) and the size of the event-related response to the picture. This map revealed regions where event-related activity was correlated positively with greater subsequent memory. There were seven focal regions where activity level reliably predicted whether pictures would be remembered, familiar, or forgotten. Six of these regions were in bilateral parahippocampal cortex and one was in the right inferior frontal sulcal region of the dorsolateral prefrontal cortex (Figs. 2 and 3, A to C). No region showed a reliable negative correlation.

In order to determine the source of the correlations between event-related study-phase activations and subsequent memory, parahippocampal activations were summed in each individual subject (14). Activations were greater for remembered than familiar pictures [$t(5) = 3.55$, $P < 0.05$] and for familiar than forgotten pictures [$t(5) = 4.56$, $P < 0.01$]. The order of activation at study in relation to subsequent memory was evident in each individual (Fig. 3D). Thus, the study phase parahippocampal activations predicted not only whether pictures would be remembered or forgotten, but also whether they would be more certainly or less certainly remembered.

Although many regions were active for picture presentation, only areas associated with declarative memory showed reliable correlations with subsequent memory. For example, fusiform regions were active for picture processing, and these regions have

Fig. 2. Composite statistical activation maps displaying voxels with significant positive correlations between event-related activations to pictures and subsequent memory for those pictures. Areas activated are right dorsolateral prefrontal cortex (upper right in slice 1) and bilateral parahippocampal cortex (lower left in slices 1 and 3; left and right in slices 2 and 4).

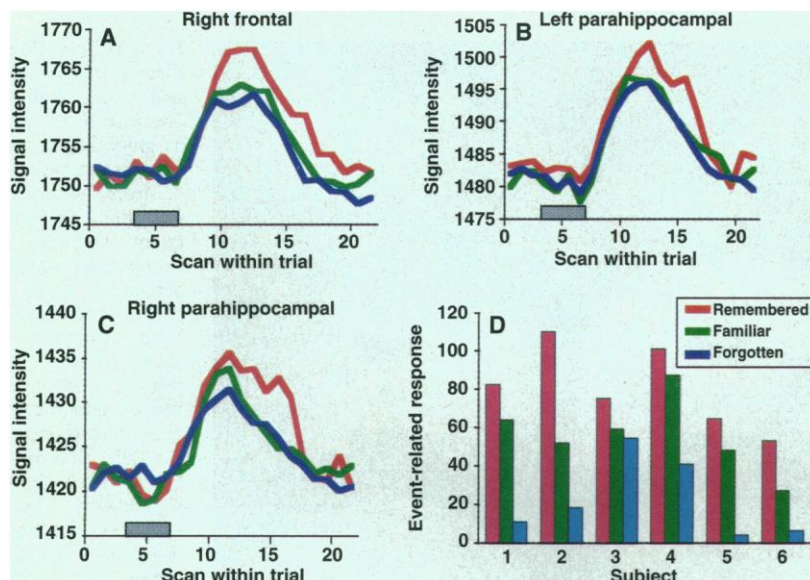
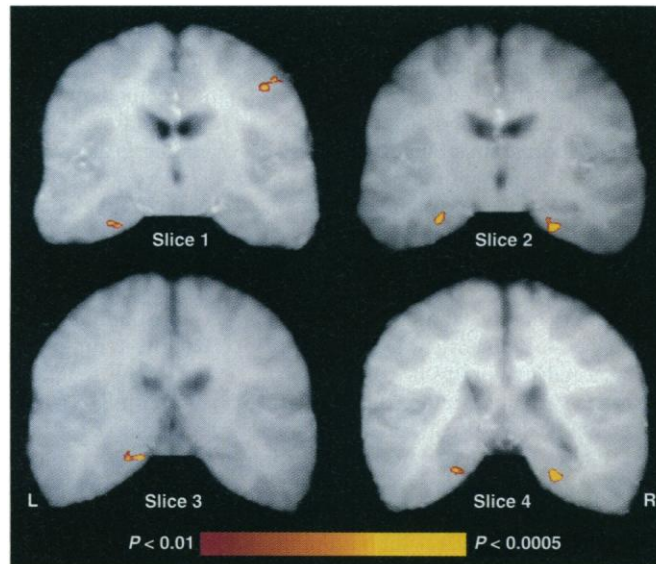


Fig. 3. Examples of average signal magnitude during study from six subjects in (A) right frontal (slice 1), (B) left parahippocampal (slice 4), and (C) right parahippocampal (slice 2) regions for remembered (red), familiar (green), and forgotten (blue) pictures. Averages were made by drawing, for each subject, regions of interest around activations that were greater for pictures than for fixation. Signal magnitude in each of these regions was averaged across subjects by trial type. Gray block depicts onset and offset of picture presentation. (D) Mean voxel response in parahippocampal areas showing significant correlation with subsequent memory in each subject for remembered, familiar, and forgotten pictures.

shown reduced activity for familiar pictures (6). The caudate, which has been linked to habit or procedural memory rather than declarative memory (15), and the anterior cingulate, which contributes to attention or performance monitoring (16), were also responsive to pictures. Only frontal and parahippocampal activations, however, predicted subsequent declarative memory.

The locations and robustness of the memory-dependent activations may be related to the visuospatial nature of the scenic stimuli (17). The right-lateralized prefrontal activation in the present study is similar in location to that found in spatial working memory tasks (18). On the basis of anatomical connections in the monkey between dorsolateral prefrontal cortex and the posterior parahippocampal cortex, it has been proposed that these two regions constitute a neural circuit that mediates the formation of spatial long-term memories (19). Thus, the results of the present study may reflect an interaction between right frontal-dependent spatial working memory processes and bilateral parahippocampal long-term memory processes that determine memory for scenes. In contrast to previous imaging studies suggesting a left-frontal lateralization for the encoding of verbal and nonverbal declarative memories, these results are consistent with lesion data suggesting a right-frontal role in the encoding of nonverbal declarative memories. However, this study did not image the entire brain, and it remains to be seen whether activations in other areas, including left frontal cortex, also predict subsequent memory for scenes.

Many factors related to encoding, storage, and retrieval contribute to determine what is remembered and what is forgotten. The findings from this study converge with other functional neuroimaging studies reporting specific and lateralized encoding-related activations for words, objects, and faces in parahippocampal and frontal regions (20). The precise nature of the psychological processes signified by these activations remains to be elucidated. The present study nevertheless indicates that the degree of activation in right frontal and bilateral parahippocampal regions measures how well a particular visual experience is encoded and therefore predicts whether it will be remembered well, remembered less well, or forgotten by an individual.

References and Notes

1. W. B. Scoville and B. Milner, *J. Neurol. Neurosurg. Psychiatry* **20**, 11 (1957); N. J. Cohen and L. R. Squire, *Science* **210**, 207 (1980).
2. J. S. Janowski, A. P. Shimamura, M. Kritchevsky, L. R. Squire, *Behav. Neurosci.* **103**, 548 (1989).
3. B. Milner, *Br. Med. Bull.* **27**, 272 (1971).
4. J. D. E. Gabrieli, J. B. Brewer, J. E. Desmond, G. H. Glover, *Science* **276**, 264 (1997).
5. E. Tulving, H. J. Markowitsch, S. Kapur, R. Habib, S. Houle, *Neuroreport* **5**, 2525 (1994).
6. C. E. Stern et al., *Proc. Natl. Acad. Sci. U.S.A.* **93**, 8660 (1996).
7. L. R. Squire et al., *ibid.* **89**, 1837 (1992); M. E. Raichle et al., *Cereb. Cortex* **4**, 8 (1994); D. L. Schacter, N. M. Alpert, C. R. Savage, S. L. Rauch, M. S. Albert, *Proc. Natl. Acad. Sci. U.S.A.* **93**, 321 (1996); J. D. E. Gabrieli, J. E. Desmond, J. B. Demb, A. D. Wagner, *Psychol. Sci.* **7**, 278, (1996); R. L. Buckner et al., *Neuron* **20**, 285 (1998).
8. T. F. Sanquist et al., *Psychophysiology* **23**, 298 (1984); K. A. Paller, M. Klutas, A. R. Mayes, *Electroencephalogr. Clin. Neurophysiol.* **67**, 360 (1987); M. D. Rugg and M. G. H. Coles, Eds. *Electrophysiology of Mind: Event-Related Brain Potentials and Cognition* (Oxford Univ. Press, Oxford, 1995).
9. R. L. Buckner et al., *Proc. Natl. Acad. Sci. U.S.A.* **93**, 14878 (1996).
10. Informed consent was obtained from all participants after the nature and possible risks of the experiment were explained. Images were acquired with a 1.5-T GE Signa whole-body scanner with a whole-head elliptical bird-cage coil [C. Hayes and C. Mathias, Proceedings of the Fourth Annual Meeting of the ISMRM, New York, 27 April to 3 May 1996 (International Society for Magnetic Resonance in Medicine, Berkeley, CA 1996)] by means of a gradient echo T2*-weighted spiral scan with two interleaves [G. H. Glover and S. Lai, *Magn. Reson. Med.* **39**, 361 (1998)]. The pulse sequence was as follows: relaxation time, 720 ms; echo time, 40 ms; flip angle, 50°; and field of view, 20 cm. Four slices perpendicular to the axial plane of the hippocampus were obtained with a 2.4-mm² in-plane and 7.0-mm through-plane resolution. The anterior slice was positioned 14 mm posterior to the head of the hippocampal formation. Structural images were acquired with a standard T1-weighted pulse sequence. Head movement was minimized by means of a bite-bar formed with each subject's dental impression, and motion artifact was examined and corrected automatically for all scans with Air 3.0 [R. P. Woods, S. R. Cherry, J. C. Mazziota, *J. Comput. Assist. Tomogr.* **16**, 620 (1992)].
11. Pictures were presented for a period of 2.88 s with an intertrial interval of 12.96 s during which a fixation cross was presented. This interval allowed the fMRI signal to rise in response to each picture presentation and to return to baseline before the next picture presentation. Thus, a separate fMRI response could be measured for each picture. Subjects (three women and three men, aged 22 to 32 years) were instructed to respond as quickly and accurately as possible and to focus on the fixation cross between picture presentations. Responses and reaction times were recorded by means of a button box with optic switches. Subjects pressed one button for indoor scenes and another for outdoor scenes.
12. Participants were instructed to view pictures presented on a computer screen and to judge if each picture had been seen during scanning. Each picture remained on the screen until the participant made a response. For pictures judged as seen during scanning, a question would appear on the screen asking the basis of that recognition. Subjects were to respond "remember" if the recognition of the picture was based on a conscious awareness of some aspect or aspects of what was experienced at the time the item was presented (for example, aspects of the physical appearance of the scene, or what one was thinking when encountering the item). Subjects were to respond "know" when recognition was made without conscious recollection of any particular aspects of its previous occurrence. As an example, participants were told that "know" was similar to what they would sense upon recognizing someone in the street without being able to recollect anything about the person.
13. There were 22 scans of brain activity per trial. Individual scans in each trial were assigned to baseline fixation or to picture classification phases on the basis of a lag in peak hemodynamic response of ~4 s after the presentation of the stimulus [D. Malonek and A. Grinvald, *Science* **272**, 551 (1996)]. Scans 1 through 6 of each trial measured activation in response to baseline fixation. Scans 10 through 15 measured activation in response to picture classification. The first statistical map, which revealed areas responding to picture presentation, compared signal from baseline scans to that of picture-classification scans for each voxel by means of a nonparametric Kolmogorov-Smirnov statistic. The second statistical map, which revealed areas predicting subsequent memory, was created as follows: For each trial, the average value from baseline scans was subtracted from scans 10 through 15. Subtracted values were integrated to measure each voxel's event-related response. A Kendall's rank-order correlation was calculated for each voxel between event-related responses and subsequent memory classification of remembered, familiar, or forgotten. Correlation coefficients were transformed into z scores. For the composite maps, the structural MRI scans were normalized into the same space to allow for the superimposition of statistical maps averaged across subjects onto an averaged structural image. The averaged activation maps were intensity thresholded at $P < 0.01$, one-tailed, and each slice was subjected to a cluster analysis procedure [J. Xiong, J.-H. Gao, J. L. Lancaster, P. T. Fox, *Hum. Brain Mapping* **3**, 287 (1995)] to correct for multiple statistical comparisons by means of a spatial extent threshold that yielded a $P < 0.01$, one-tailed, significance level over the entire image. Significant voxels were colored according to their level of significance and were overlaid on the averaged structural image. Regions where activity correlated positively with subsequent memory were examined on brain images normalized to the stereotaxic space of Talairach and Tournoux [J. Talairach and P. Tournoux, *Co-Planar Stereotaxic Atlas of the Human Brain* (Thieme, New York, 1988)]. Coordinates for the activations are as follows: right frontal (40, 15, 32); right parahippocampal in slice 2 (22, -35, -15) and slice 4 (24, -48, -8); and left parahippocampal in slice 1 (-34, -29, -18), slice 2 (-33, -34, -13), slice 3 (-27, -40, -9), and slice 4 (-29, -46, -6).
14. For each subject, regions of interest were drawn around parahippocampal activations showing significant positive correlation with subsequent memory. Event-related responses (calculated for each voxel as described above) were averaged in the activated regions for pictures that were subsequently remembered, familiar, or forgotten.
15. J. A. Saint-Cyr, A. E. Taylor, A. E. Lang, *Brain* **111**, 941 (1988); B. J. Knowlton, J. A. Mangels, L. R. Squire, *Science* **273**, 1399 (1996).
16. S. E. Petersen, P. T. Fox, M. I. Posner, M. Mintun, M. E. Raichle, *Nature* **331**, 585 (1988); C. S. Carter et al., *Science* **280**, 747 (1998).
17. G. K. Aguirre, J. A. Detre, D. C. Alsop, M. D'Esposito, *Cereb. Cortex* **6**, 823 (1996); R. Epstein and N. Kanwisher, *Nature* **392**, 598 (1998); E. A. Maguire et al., *Science* **280**, 921 (1998).
18. M. D'Esposito et al., *Cogn. Brain Res.* **7**, 1 (1998).
19. P. S. Goldman-Rakic, L. D. Selemon, M. L. Schwartz, *Neuroscience* **12**, 719 (1984).
20. J. V. Haxby et al., *Proc. Natl. Acad. Sci. U.S.A.* **93**, 922 (1996); R. J. Dolan and P. C. Fletcher, *Nature* **388**, 582 (1997); A. Martin, C. L. Wiggs, J. Weisberg, *Hippocampus* **7**, 587 (1997); S. A. Rombouts et al., *ibid.*, p. 594; W. M. Kelly et al., *Neuron* **20**, 927 (1998); A. D. Wagner et al., *Science* **281**, 1188 (1998).
21. Supported by grants from the National Institute on Aging and the National Center for Research Resources. J.B.B. was supported by a Medical Scientist Training Program grant awarded by the National Institute of General Medical Sciences. We thank two anonymous reviewers for helpful comments, R. Poldrack and G. Fernandez for stimulating discussions, and E. Thomas, W. Francis, and C. Vaidya for advice on analysis and this manuscript.

19 May 1998; accepted 20 July 1998