

Endocranial Capacity in an Early Hominid Cranium from Sterkfontein, South Africa

Glenn C. Conroy,* Gerhard W. Weber, Horst Seidler,
Phillip V. Tobias, Alex Kane, Barry Brunnsden

Two- and three-dimensional computer imaging shows that endocranial capacity in an ~2.8- to 2.6-million-year-old early hominid cranium (Stw 505) from Sterkfontein, South Africa, tentatively assigned to *Australopithecus africanus*, is ~515 cubic centimeters. Although this is the largest endocranial capacity recorded for this species, it is still markedly less than anecdotal reports of endocranial capacity exceeding 600 cubic centimeters. No australopithecine has an endocranial capacity approaching, let alone exceeding, 600 cubic centimeters. Some currently accepted estimates of early hominid endocranial capacity may be inflated, suggesting that the tempo and mode of early hominid brain evolution may need reevaluation.

Understanding the tempo and mode of human brain evolution remains one of paleoanthropology's greatest challenges. Much of the difficulty derives from the fact that there are still relatively few early hominid crania for which reasonable estimates of endocranial capacity (used as a surrogate for actual brain size in paleontological studies) can be determined. For this reason, each new fossil discovery that provides reasonable endocranial capacity estimates is extremely important for models of early hominid brain evolution.

In 1989 the late Alun R. Hughes recovered a large hominid cranium, Stw 505, in situ from Sterkfontein Member 4, dated to ~2.8 to 2.6 million years ago (1). The specimen, which we have dubbed "Mr. Ples," preserves much of the face and left side of a large, presumably male, adult cranium and is the most complete early hominid cranium recovered from Sterkfontein since the discovery of Sts 5 ("Mrs. Ples") just over 50 years ago (Fig. 1).

The specimen has recently been cited as an example of *Australopithecus africanus* and has been anecdotally reported as

having an endocranial capacity exceeding 600 cm³ (2). Such an endocranial capacity, if correct, would be astounding in any australopithecine, let alone one dated to such antiquity. It would exceed the largest published *A. africanus* endocranial capacity by over 100 cm³ and would approximate, or even exceed, the endocranial capacity of several early *Homo* specimens from East Africa nearly 500,000 to 1,000,000 years younger in age [for example, OH 16 (638 cm³), OH 24 (594 cm³), KNM-ER 1805 (582 cm³), and KNM-ER 1813 (510 cm³)]. The sample range of endocranial capacity values for *A. africanus* would more than triple from the current extent of 60 cm³ (425 to 485 cm³) and the mean value for endocranial capacity would increase from 440 cm³ to over 460 cm³. Thus, verification of this estimate of "Mr. Ples" endocranial capacity is needed.

To evaluate the endocranial capacity of this remarkable yet incomplete specimen, we first generated a complete series of high-resolution, 1-mm-thick, transaxial computed tomography (CT) scans of the cranium. Even though the cranium is heavily mineralized, the CT scans do not have any noticeable artifacts like beam-hardening or scattering and preserve the full spectrum of internal details of osteological structures. From these CT data we then produced a geometrically accurate three-dimensional (3D) computer model of the cranium (Fig. 1) (3). We tested the reconstructed cranium for accuracy by comparing linear measurements against the original specimen. Accuracy was within 0.5%. Even though there is some plastic deformation in the facial skeleton of Stw 505, particularly in the maxilla, the midsagittal plane of the endocranium is easily identified by the presence of a well-developed frontal crest for attachment of the falx cerebri. We used such midline landmarks to model a complete 3D cranium, including the missing portions, by mirror-imaging the specimen assuming that symmetry is bilateral around this midsagittal plane (Fig. 2).

The program allowed the enclosed endocranial cavity to be rendered as a separate 3D object ("virtual endocast") and calculated its volume directly (Fig. 3). The resulting "virtual endocast" of "Mr. Ples" has a volume of 513 cm³.

We checked the accuracy of our 3D computer model by making the cranial bones transparent in order to visualize the virtual endocast. As can be seen in Fig. 3 there is no obvious incongruity between the volume-rendered cranium and its volume-rendered endocranial cavity. In other

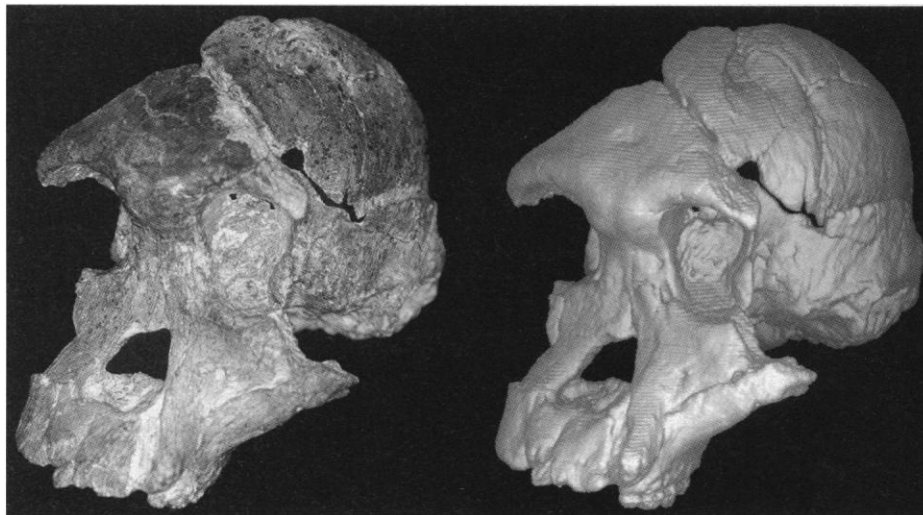

Fig. 1. Stw 505. (Left) Original specimen; (right) computer-generated 3D reconstruction from serial CT data.

G. C. Conroy, Department of Anatomy and Neurobiology and Department of Anthropology, Washington University School of Medicine, St. Louis, MO 63110, USA.

G. W. Weber and H. Seidler, Institute of Human Biology, University of Vienna, Althanstrasse 14, A-1090 Vienna, Austria.

P. V. Tobias, Department of Anatomical Sciences, University of the Witwatersrand Medical School, Johannesburg, South Africa.

A. Kane, Division of Plastic Surgery, Washington University School of Medicine, St. Louis, MO 63110, USA.

B. Brunnsden, Mallinckrodt Institute of Radiology, Washington University School of Medicine, St. Louis, MO 63110, USA.

*To whom correspondence should be addressed at the Department of Anatomy and Neurobiology, Box 8108, Washington University School of Medicine, St. Louis, MO 63110, USA. E-mail: conroy@thalamus.wustl.edu

words, this smaller than expected endocranial capacity determination was not produced because we somehow missed part of the endocranium in generating our computer model. On the contrary, there is a gap between the left parietal and temporal bones along the squamosal suture that artificially increases the virtual endocast volume by about 8 cm³, artificially enlarging the total volume by ~16 cm³. We further tested the reliability of our virtual endocast method with high-resolution scans of 10 *Homo sapiens* skulls and compared the computed endocranial capacity results against known capacity determined directly by filling each cranium with mustard seed. The observed error was ~2% of the total volume (4).

We also calculated endocranial volume for every relevant 1-mm CT slice in the entire data set, 106 slices in all. Endocranial volume determined by this method resulted in a value of 518 cm³, very close to the virtual endocast value.

We further verified these computer-generated results by calculating the volume of water needed to fill the endocranium using a detailed cast of the original specimen. We built up from Plasticine the missing portions of the posterior cranial fossa and then filled half the endocranium with water, so that the meniscus coincided with the median sagittal plane. The water was then carefully poured into a graduated cylinder (tolerance \pm 10 ml) and its volume recorded. Total endocranial capacity was determined by simply doubling this figure and subtracting 16 cm³ from this total, our estimate of increased volume caused by plastic deformation along the squamosal suture. This test was repeated nine times, resulting in a mean endocranial

capacity determination of 515 cm³ (range of 482 to 536 cm³). Thus, all methods are consistent with an endocranial capacity estimate of ~515 cm³ for "Mr. Ples" (5).

Even though a value of about 515 cm³ is much smaller than earlier anecdotal reports about this cranium, it still exceeds the largest value for six other *A. africanus* crania so far determined or estimated, such as that of "Mrs. Ples" (Sts 5) with a capacity of 485 cm³. It is of course possible that Stw 505 may represent a new hominid taxon at Sterkfontein, but only further study will resolve that issue (6).

Our calculations for Stw 505 suggest that it would be worthwhile to reexamine endocranial capacity estimates for other early hominids, upon which all theories concerning the tempo and mode of human brain evolution are based [for estimates of early hominid endocranial capacities, see (7–10)]. Superficial inspection of the exterior of some early hominid crania such as OH 24, KNM-ER 1813, and

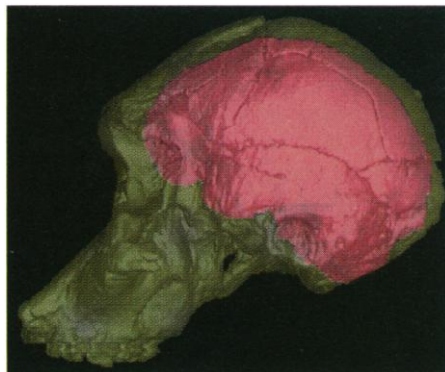


Fig. 3. Cranium of Stw 505 rendered transparent in order to visualize its "virtual endocast."

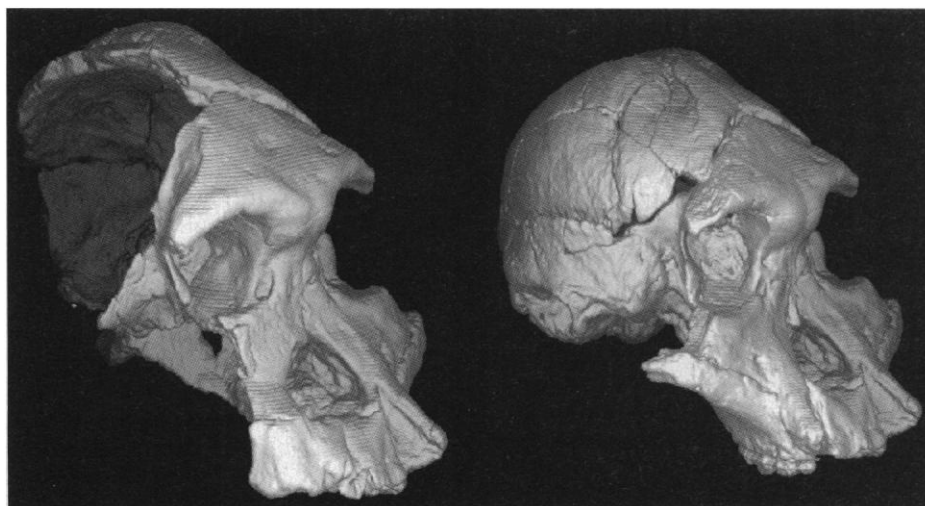

Fig. 2. (Left) computer-generated 3D reconstruction of Stw 505; (right) computer-generated 3D mirror-image model of Stw 505 with "missing" portions of the cranium reconstructed.

KNM-ER 732 suggest that these calvariae are smaller than that of Stw 505, yet published endocranial capacity estimates for these three specimens are similar to, or even larger than, the value for Stw 505 (594, 510, and 506 cm³, respectively). Furthermore, endocranial capacity measured by water volume in a detailed cast of another *A. africanus* specimen, Sts 71, shows that its endocranial capacity was probably closer to 370 cm³, very near the mean value for female chimpanzees, and not the currently accepted 428 cm³ (7–10).

The recognition that no australopithecine has an endocranial capacity approaching, let alone exceeding, 600 cm³, and that several key early hominid endocranial estimates may be inflated, suggests that current views on the tempo and mode of early hominid brain evolution may need reevaluation.

REFERENCES AND NOTES

1. P. V. Tobias, "23rd Annual Report of the Palaeo-Anthropology Research Unit" (Univ. of the Witwatersrand, Johannesburg, 1989).
2. D. Johanson and B. Edgar, *From Lucy to Language* (Simon & Schuster, New York, 1996).
3. CT scans were taken on a Siemens Somatom Plus4 CT scanner at Selby Park Medical Centre, Marshalltown, South Africa. The density histogram values for the fossil lie between 1800 and 3000 Hounsfield units (HU), whereas normal bone is normally between about 400 and 3000 HU. The CT settings were as follows: matrix = 512 \times 512, scan time = 1.5 s, kilovoltage (kV) = 140, milliamperes (mA) = 129, 12-bit gray scale, and pixel size of 0.39 mm. Computer models were made with ANALYZE software on a Silicon Graphics Workstation.
4. H. Seidler *et al.*, *J. Hum. Evol.* **33**, 691 (1997); G. Weber *et al.*, *Am. J. Phys. Anthropol. Suppl.* **26**, 228 (1998).
5. Other more indirect, subjective measures also give us confidence that this value is a reasonable one. For example, the parietal fragments of the OH-5 cranium ("Zinj") fit "Mr. Ples" precisely (in fact, if anything, are slightly large for "Mr. Ples"). "Zinj" has an estimated endocranial capacity of 530 cm³.
6. R. J. Clarke, in *Integrative paths to the past*, R. S. Corruccini and R. L. Ciochon, Eds. (Prentice-Hall, Englewood Cliffs, NJ, 1994), pp. 205–222; C. A. Lockwood, thesis, University of the Witwatersrand, Johannesburg (1997).
7. R. Holloway, *Can. J. Anthropol.* **3**, 215 (1983).
8. P. V. Tobias, *Olduvai Gorge IV: The Skulls, Endocasts and Teeth of Homo habilis* (Cambridge Univ. Press, Cambridge, 1991).
9. ———, in *Integrative Paths to the Past*, R. S. Corruccini and R. L. Ciochon, Eds. (Prentice-Hall, Englewood Cliffs, NJ, 1994), pp. 185–203.
10. G. C. Conroy *et al.*, *Science* **247**, 838 (1990).
11. Supported by a grant from NSF, as well as grants for the excavation at Sterkfontein from the Foundation for Research Development and the Witwatersrand University. We thank D. J. Emby, S. Ralph, D. Zur Nedden, R. Clarke, H. White, L. Boscombe, L. Berger, Siemens (South Africa), Selby Park Medical Centre (Johannesburg), and Zumtobel (Austria) for their support in various phases of this research. We dedicate this work to the late Alun Hughes.

2 March 1998; accepted 10 April 1998