

Injections and observations were continued until death of the animal or until the approach of the moribund state, when animals were killed for study.

In addition, urethane was administered daily to normal C strain mice in amounts similar to those given to the second group of leucemic mice.

Among other criteria of the effectiveness of the drug, the life span of each animal was of considerable importance. This measurement was markedly affected in the first series of mice by the development of pneumonia in three-fourths of the treated animals. It was not realized until the pathologic sections were studied that this pneumonia was superimposed on, and probably was secondary to, a relatively mild pulmonary edema, which was present in all the treated animals. In the second series, which received the largest amount of urethane, the life span was also reduced by the development of pulmonary edema of a more severe and more rapidly fatal variety in all of the animals. This occurred not only in the leucemic but also in the normal C strain animals receiving similar doses of urethane. In the third series of animals, graded doses of urethane were used in an effort to attain control of the leucemia without the development of pulmonary edema. Doses sufficiently large to result in a reduction of the total leucocyte count with a shift to the right and a reduction in the sizes of the liver, spleen, and lymph nodes caused pulmonary edema in all of the cases. The smaller doses of urethane were ineffectual in maintaining an initially favorable response, and even these ineffective amounts resulted in the development of pulmonary edema of lesser degree in many of the animals. In this latter group, death resulted, if not immediately from the edema, several days later from pneumonia. Other evidences of capillary damage throughout the body were seen grossly in a large percentage of these cases.

At necropsy, animals with pulmonary edema frequently showed the customary accumulations of pinkish-brown, frothy material about the nares and mouth. On opening the thorax, fluid, usually of a serosanguineous nature, was frequently encountered. The lungs were always tense, completely filling the thorax. Their appearance varied from a pinkish-brown, almost translucent character to a mottled bright and deep red. Petechiae were often seen. On section of the trachea, as well as of the lung parenchyma, large quantities of fluid exuded, after which the lung became quite compressible. Microscopically, the alveoli and the bronchi were distended and filled with a pink-staining homogeneous material. There was marked capillary engorgement with evidence of rupture and release of erythrocytes into the alveoli. Areas of bronchopneumonia were present in animals in which the pulmonary edema was less severe and not immediately fatal.

Although edema in these animals was almost entirely confined to the lungs, other evidences of capillary damage were noted. The axillary and inguinal regions were, in nearly all cases, sites of subcutaneous petechiae and frequently of localized anasarca. The site of intraperitoneal injection (constant because of anatomic reasons) often revealed subcutaneous petechiae progressing at times to

ecchymoses. From the low incidence in the untreated controls it may be assumed that these phenomena are not due solely to thrombocytopenia secondary to leucemia. The comparative gross data relative to the foregoing observations are presented in Table 1.

Although we realize that observations on laboratory animals can seldom be applied directly to man, it is the aim of this paper to increase the awareness of the toxic potentialities of urethane, when used over a period of time, particularly with respect to capillary damage.

References

1. GOODMAN, L. S., and GILMAN, ALFRED. *The pharmacological basis of therapeutics*. New York: Macmillan, 1941.
2. KIRSCHBAUM, ARTHUR, and BELL, E. T. *Proc. Soc. exp. Biol. Med.*, 1947, **64**, 71-72.
3. KROGH, A., and HARROP, G. A. *J. Physiol.*, 1921, **54**, cxxv-cxxvi.
4. LANDIS, E. M. *Amer. J. Physiol.*, 1927, **81**, 124-142.
5. MOON, V. H., and MORGAN, D. R. *Arch. Path.*, 1936, **21**, 565-577.
6. SOLLMANN, TORALD. *J. Pharm. exp. Therap.*, 1917, **9**, 391-392.
7. WEBSTER, J. J. *J.A.M.A.*, 1947, **135**, 901-903.

Use of Radioactive Diiodofluorescein in the Diagnosis and Localization of Brain Tumors¹

GEORGE E. MOORE²

Department of Surgery,
University of Minnesota Medical School, Minneapolis

The use of fluorescein has recently been suggested as an aid in the diagnosis of malignancy (1). In the initial report it was observed that brain tumors appeared to exhibit a consistent special affinity for the absorption of previously injected fluorescein.

In an attempt to extend the clinical usefulness of the fluorescein technique, radioactive derivatives of the dye have been prepared. Since it is considered safe to use, for clinical purposes, only those isotopes with a short half-life, and since the detection of deep-seated intracranial lesions requires the emission of gamma radiation, diiodofluorescein was synthesized to contain I¹³¹. The amount of I¹³¹ added was adjusted to give 1 mc of radioactivity/10 cc of a 2% solution of the final product, sodium diiodofluorescein. An amount of dye calculated to contain 500-600 μ c of radioactivity was injected intravenously in each case. In order to give a comparable dose of radioactivity to patients on subsequent days,

¹This research was supported by a grant from the National Cancer Institute and the U. S. Public Health Service, the Malignant Disease Research Fund, and the Flora L. Rosenblatt Fund for Cancer Research.

The author wishes to express his appreciation to W. T. Peyton and his staff for making the clinical cases available and to J. F. Marvin, of the Department of Biophysics, for much helpful advice.

²Senior Research Fellow, U. S. Public Health Service.

increasing volumes of the dye were injected as the I^{131} decayed. Previous toxicity studies have shown that the ML/50 of diiodofluorescein is comparable to that of eosin; no toxic reactions have been encountered from the small amount of dye administered.

All counts were obtained by means of a beta-gamma Geiger-Müller tube protected from background radiation by a 2-cm-thick lead shield, provided with a lead cone to reduce the area being counted, and mounted on a portable X-ray unit. Thin lead foils were placed over the counter window to filter out beta radiation. A quenching circuit attached directly to the Geiger-Müller tube from the scaler allowed easy manipulation of the detection unit over the patient. Counts were taken for 3- to 5-min intervals at each of several positions on the skull with the cone of the detection unit directly on the skin. An

of the brain with the exception of the area over the tumor, where the highest counts are recorded. In cases in which the tumor is accompanied by a large amount of edema, somewhat higher counts may be obtained over the entire affected hemisphere. As experience with the technique increased, a single series of counts at the proper interval was found satisfactory to localize the tumor. A majority of the tests were carried out without knowledge of the neurological findings, roentgen examination, and staff opinion. Only cases with questionable intracranial neoplasms were examined by this method.

To date 15 patients suspected of harboring intracranial neoplasms have been subjected to this technique. The last 12 cases are summarized in Table 1. Three previous cases with known site of recurrence, following previous partial operative excision, were studied by the

TABLE 1

		Clinical preoperative diagnosis	Conclusions from radioactive dye technique	Operative findings
(1)	K.W.	Meningeoma of right sphenoid ridge	No tumor	Aneurysm of right internal carotid
(2)	E.S.	(?)Tumor of right temporal or parietal lobe	Tumor of right parietal occipital area	Ependymal blastoma, right occipital lobe
(3)	T.B.	Tumor of right temporal lobe	(?)Tumor of right temporal area	Meningeoma of right middle fossa
(4)	P.K.	Metastatic tumor of right parietal lobe	Tumor in right parietal area	Metastatic tumor of right parietal lobe
(5)	L.S.	(?)Metastatic tumor of right motor cortex	No tumor on right; (?) tumor of left frontal lobe	No tumor on right, left side not explored
(6)	H.L.	(?)Tumor	Tumor of posterior frontal lobe on right	Glioblastoma of right temporal lobe
(7)	J.H.	Tumor of right frontal lobe	Tumor of right frontal lobe	Ependymal blastoma of right frontal lobe
(8)	J.B.	(?)Tumor	Tumor to left of the midline, posterior frontal area	Meningeoma of left posterior frontal area
(9)	G.H.	(?)Tumor	No tumor	Normal ventriculogram, no operation
(10)	E.J.	Large tumor of right parietal lobe	Tumor of right parietal area	Right parietal tumor by ventriculogram and biopsy
(11)	L.W.	Right acoustic neuroma	No significant counts	Right acoustic neuroma
(12)	A.B.	Subdural hematoma, right side	Tumor of right frontal lobe near midline	Meningeoma of right frontal lobe near midline

attempt was made to obtain counts over symmetrical positions on the right and left sides of the head, as well as counts along the midline. After a complete survey, an examination of sites of higher activity was repeated in order to localize more definitely the suspected lesion. At times uncooperativeness of a patient due to the intracranial lesion made an adequate survey impossible.

Although counting was begun soon after dye was injected, differential readings between areas over the suspected tumor and symmetrical control areas did not become evident until an interval of 2-4 hrs had elapsed. This interval, required for the development of maximal differences in concentration of dye by the normal and tumor tissue, corresponds closely to the time lag prior to the appearance of maximal fluorescence noted in the earlier study (1) of brain tumors. Soon after the dye is injected, higher counts are obtained over the large venous sinuses; then, as the dye is removed from the blood stream, the counts tend to equalize over all parts

radioactive dye method before the diagnosis of new cases was attempted.

Correct diagnoses of negative findings (Cases 1 and 9), as well as positive, have been made. Case 12 is of special interest. From the results of the counts obtained with the radioactive dye technique, a definite area was outlined on the skull over the site of the tumor. This outline coincided closely to the extent of the superficially situated meningeoma found at operation.

The limitations of this technique are as yet unknown, and its clinical usefulness is still to be determined. Further studies of the differential concentration of the radioactive dye in normal and edematous brain tissue as well as various tumors, clinical and experimental, are in progress. Preliminary experiments utilizing induced brain tumors in mice have revealed the concentration of dye in the tumor tissue to be as high as 80 times that found in the adjacent normal brain. Measurements of various concentrations of radioactive diiodofluorescein

under physical conditions simulating those found clinically have verified the feasibility of the technique and will be reported upon later.

Reference

1. MOORE, G. E. *Science*, 1947, **106**, 130-131.

Similarity to Heparin of the Clotting Inhibitor in Acute Leucemia and the Significance of Hyperheparinemia in Estrapenic Cholinergic States

ROBERT D. BARNARD

Terrace Heights Hospital, Hollis, Long Island

Heparin, the antithrombin of normal blood (6), is reported to be increased in instances of human pernicious anemia and leucoses (2, 9), in anaphylactic and peptone shock (7), and, more recently, in radiation morbidity in dogs (1). The basis for its identification in these conditions has been neutralization of thrombin (2, 9) or neutralization by globin (2) or by toluidine blue (1).

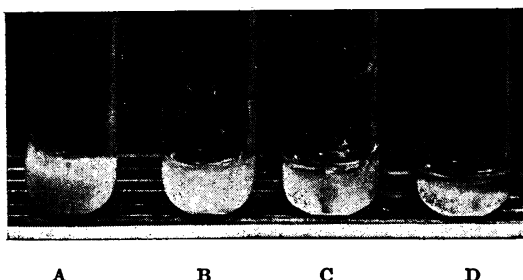


FIG. 1. Human plasma clots formed by addition of Russell viper venom and calcium chloride to normal citrated plasma: A, normal clot; B, clot formed in presence of 1 mg% of heparin; C, 2 mg% of heparin; D, after dilution with an equal volume of plasma from a patient with terminal hemorrhagic acute leucemia.

Additional evidence for the heparin identity of the antithrombin in 5 patients with acute leucosis and 2 with thrombotic cardiogenic shock has been secured. Addition of the plasmas of these patients to citrated normal human plasma caused a dissociation in the precipitation rates of filiar and gelatinous fibrin when the plasma was clotted by calcium chloride-viper venom. In untreated citrated human plasma, the opaque filiar fibrin component (which appears to be precipitated through direct thromboplastin-fibrinogen interaction and is responsible for clot retraction, 4) precipitates immediately prior to the formation of gelatinous fibrin (resulting from thrombin-fibrinogen interaction, the nonretractile, fibrinolyzable component), so that both components are disseminated uniformly throughout the body of the resulting opaque clot (Fig.

¹ The observations recorded were made at Halloran General Hospital, Staten Island, prior to its closing as an Army installation. The kind cooperation and sponsorship of Maj. Helmuth Sprinz, Chief of Laboratory Service, is gratefully acknowledged.

1A). In the presence of 1 mg% of heparin, gelatinization is delayed until retraction of the filiar fibrin has begun, so that both components of the clot can be separately distinguished (Fig. 1B). Dissociation is usually completed by the presence of 2 mg% of heparin (Fig. 1C). Fig. 1D shows the degree of dissociation produced by an added equal volume of the incoagulant plasma from a patient in the hemorrhagic phase of acute myeloblastosis, which indicates for this plasma a heparin content of between 2 and 3 mg%. Confirmation of this approximate figure for the heparin content of this patient's blood was secured by thrombin titration.

Hyperheparinemia of this extent, while explaining incoagulability, cannot, in itself, condition the hemorrhagic diathesis. Equal or greater heparin concentrations are frequently attained, temporarily at least, in human blood, since it is now common clinical practice in the treatment of thrombophlebitis to administer 100 mg of heparin by single intravenous injections. During dicumerol therapy, occasional patients who exhibit a spontaneous autochthonous hyperheparinemia have been encountered without relationship to any tendency to capillary bleeding.

Attention has been directed to the apparent limitation of hyperheparinemic extravasation to the estrapenic conditions, those characterized or attended by a diminution in the blood cholinesterase concentration (5). Estrapenia, per se, might explain hyperheparinemic extravasation on the basis of cholinergic capillary paresis, but the possible interrelationships of estrapenia and hyperheparinemia have not hitherto been clarified. By the citation of some additional facts, their corollaries and elaborations, it may now be justifiable to attempt an explanation of the mechanism of hyperheparinemia arising during the estrapenic dyscrasias.

(1) The administration of heparin to a subject with normal hemopoietic function is followed, after the usual period of diminished blood coagulability, by a hypercoagulability state. This is familiar to clinicians as the "heparin rebound," which may occur if too long an interval is allowed between successive heparin administrations in the treatment of thrombophlebitis and by which the condition may actually be aggravated. Heparin hypercoagulability may also be demonstrated in the rabbit and the dog; in the latter animal the writer has seen coagulation times of 20-30 sec, 4 hrs after administration of coagulation-abolishing doses of heparin.

(2) During heparin rebound, the thromboplastin concentration of the blood is markedly increased, while in the hemorrhagic phase of estrapenic hyperheparinemia it is considerably diminished (3). In the thrombopenic forms of the acute malignant hematologic dyscrasias, even where coagulation time is apparently normal, the filiar fibrin component of the clot and clot retraction may both be absent. Since thromboplastin enters directly into the formation of the retractile filiar fibrin (3), thromboplastin deficiency in these states is further indicated.

(3) The elaboration of the major fraction, at least, of the blood (erythrocytic) cholinesterase is a hemopoietic marrow function (8). This is likewise true of the elaboration of the major fraction, at least, of the